Fascial Manipulation® Workshop

Clinical study of

Carpal Tunnel Syndrome (CTS)



Andrea Pasini PT

Anatomy

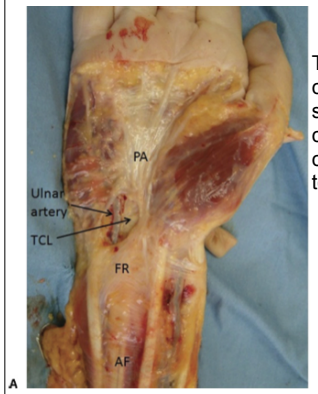

Two different fibrous structures with different histological characteristics are present in the volar wrist: the more superficial one is in continuity with the antebrachial fascia and could be considered its reinforcement; the deeper one is composed of strong lamina, with histological features similar to those of a ligament

Stecco C , Macchi V, Lancerotto L, Tiengo C, Porzionato A, De Caro R.;Comparison of transverse carpal ligament and flexor retinaculum terminology for the wrist. J Hand Surg Am. 2010 May;35(5):746-53. Epub 2010 Mar 25.

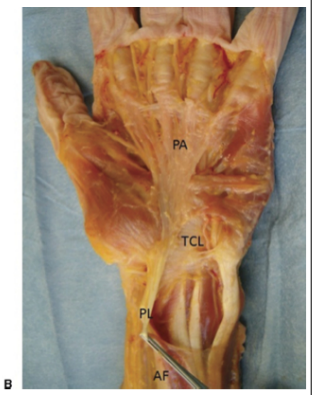

A Flexor retinaculum (FR) is in continuity with the antebrachial fascia (af), it forms the Guyon's canal roof;the floor consists of the transverse carpal ligament (TCL). B Flexor retinaculum dissected on the radial side with the palmaris longus tendon (PL) to show the transverse carpal ligament (TCL). PA, palmar aponeurosis

The fascial planes of the wrist

The MRI images permit to appreciate the relationships between the flexor retinaculum of carpi and the transverse carpal ligament.

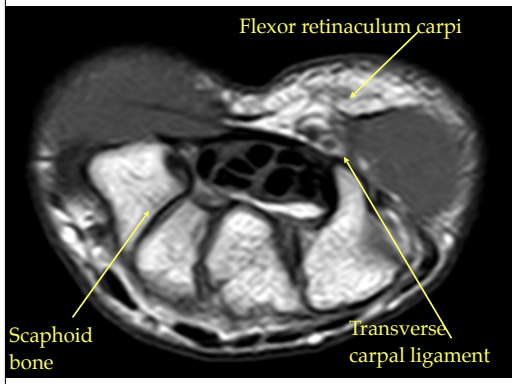

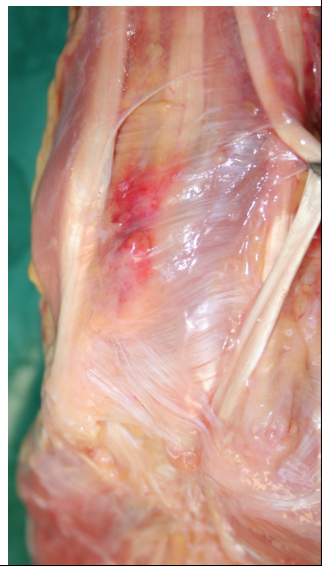

- Antebrachial flexor retinaculum, thickening of distal antebrachial fascia just proximal to radiocarpal joint. Continuous with extensor retinaculum at margins of forearm. This structure **is distinct** from the transverse carpal ligament, commonly called "the flexor retinaculum" which forms the roof of the carpal tunnel
- Syn. Flexor retinaculum of forearm, palmar carpal ligament. (Stedman's, 1995)

What is CTS

Carpal Tunnel Syndrome (CTS) is the most common compression neuropathy and is due to compression of the median nerve (Ibrahim et al., 2012).

Symptoms
- pain and paresthesia in the first, second and third fingers along the innervations of the median nerve

Etiopathogenesis
- multifactorial and in most cases idiopathic (Marshall, 2001)

Main Causes
- trauma (including previous fractures of the wrist or joint deformity), arthritis and arthrosis (Mahoney and Dagum, 1992).
- deformation of me- dian nerve (Hunter, 1991),
- stiffness and fibrosis of the transverse carpal ligament (Nakamichi and Tachibana, 1995),
- hypertrophy of thenar eminence with increased pressure into the carpal tunnel (Nakamichi and Tachibana, 1995; Rojviroj et al., 1990),

fibrosis that reduces median nerve mobility (Phalen, 1970).

Symptoms

Carpal Tunnel Syndrome (CTS) is the most common compression neuropathy and is due to compression of the median nerve (Ibrahim et al., 2012).

Pain
- wrist, irradiation to the hand, severe, nocturne

Paresthesia
- pins and needles in the region of median nerve

hypoesthesia
- thermal pain sensitivity

anterograde symptoms
- pain/paresthesia irradiated to the upper arm or to the shuolder

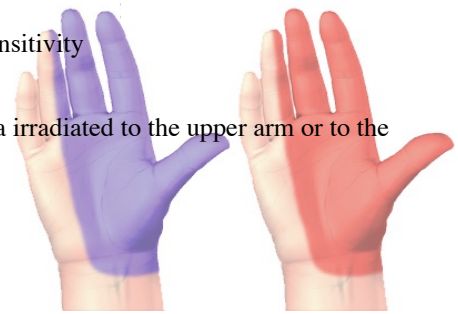

Other Treatments

Currently, there is inadequate scientific evidence regarding conservative treatments

- The benefits and risks related to the use of night time orthotic (Page et al., 2012a,b,c),
- exercises and mobilization (,,), therapeutic ultrasound (,,) and equipment, such as ergonomic computer keyboards (O'Connor et al., 2003), are not known.
- The injection of corticoste- roids is effective in reducing edema and local inflammation (Marshall et al., 2007; Marshall, 2001). However, the beneficial effects are inconsistent and not devoid of collateral effects (for instance, reduced synthesis of collagen and proteoglycans with consequent tissue atrophy) (Tsai et al., 2003; Scutt et al., 2006).
- Low intensity laser therapy (LLLT) seems to be able to decrease the pain and associated symptoms and to increase the strength and function while also stimulating the proliferation of fibro- blasts, the microcirculation and acetylcholinesterase ac- tivity (Kujawa et al., 2003) in mild cases of CTS (Chang et al., 2008; Dakowicz et al., 2011; Yagci et al., 2009; Elwakil et al., 2007)

Other Treatments

Evidence based on the use of selected manual therapies appears to be more promising

- relief of median nerve compression by chiropractic manipulation and manual therapy. Valente and Gibson, 1994; Maddali et al., 2013
- a study carried out on a small group of patients affected by CTS, subjected to myofascial therapy and stretching, evaluating patients before and after treatment with nuclear magnetic resonance, demonstrated an increase in the size of the antero-posterior and transverse carpal tunnel (Sucher, 1994, 1993)
- the same author showed in cadavers that osteopathic manipulation was able to elongate the carpal tunnel ligament and suggested that such techniques may be of use in nonsurgical relief of pressure on the median nerve in patients with CTS (Sucher, 1993)

Other Clinical Studies

A manual therapy intervention improves symptoms in patients with carpal tunnel syndrome: a pilot study

Maddali Bongi S., Signorini M., Bassetti M., Orlandi M., De Scisciolo G. ; J. Orthop. Res. 2012 Aug; 30(8);1343-50.

- 22 patients with CTS (41 hands)
- 6 treatments: 2/week for 3 weeks
- Deep transverse friction cyriax
- Evaluation: symptomatic/functional scale and EMG
- Follow-up at the end of treatments and after 24 weeks
- Results: functional and symptomatic improvement, maintained at the follow-up

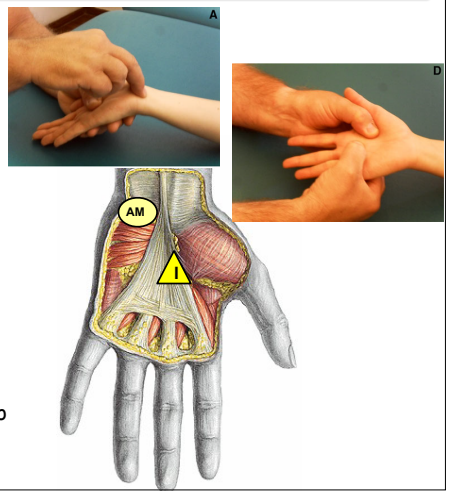

Other Clinical Studies

Response of pain intensity to soft tissue mobilization and neurodynamic tecnique: a serie of 18 patients with chronic carpal tunnel syndrome: a pilot study

- 18 patients with CTS (41 hands)
- 6 treatments: 2/week for 3 weeks
- Evaluation: symptomatic/functional scale
- Follow-up at 1 week after the treatments
- Results: functional and symptomatic improvement

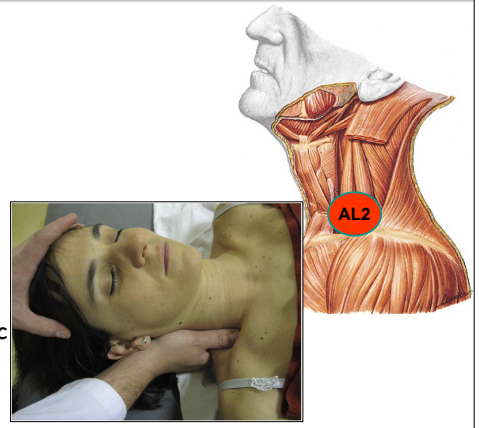

Journal of Manipulative and Physiological Therapeutics, 2012

Other Clinical Studies

Myofascial manipulative release of the carpal tunnel syndrome: documentation with RMI

Sucher BM (1993) Myofascial manipulative release of carpal tunnel syndrome: documentation with magnetic resonance imaging. J Am Osteopath Assoc 93:1273–1278 J. American Osteopatich Assoc. , 1993

- Myofascial therapy and stretching in patients with CTS
- Evaluation of the carpal tunnel dimension with RMI

Results:

- Aumentate significativamente dimensioni trasverse e antero-posteriori tunnel carpale.
- Significantly increased the transverse and ante-posterior dimensions of the carpal tunnel
- Decrease of the symptomatology and improving of the nerve conduction

Our Clinical Study

Several other studies have shown that Fascial Manipulation" (FM) was able to decrease pain, restore the movement and muscle strength in a case of patellar tendinopathy (Pedrelli et al., 2009), post traumatic sub-acute neck pain (Picelli et al., 2011), chronic shoulder pain (Day et al., 2009) chronic ankle instability (Stecco et al., 2011) and tmj disorders (Guarda-Nardini et al., 2012)

The purpose of our study was to compare the effectiveness of Fascial Manipulation© to Low-Level Laser Therapy in carpal tunnel syndrome

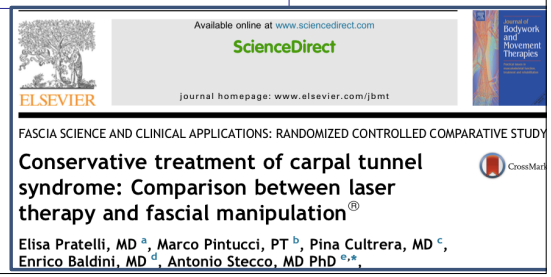
Available online at www.sciencedirect.com
ScienceDirect
journal homepage: www.elsevier.com/jbmt
ELSEVIER

FASCIA SCIENCE AND CLINICAL APPLICATIONS: RANDOMIZED CONTROLLED COMPARATIVE STUDY

Conservative treatment of carpal tunnel syndrome: Comparison between laser therapy and fascial manipulation®

Elisa Pratelli, MD [a], Marco Pintucci, PT [b], Pina Cultrera, MD [c], Enrico Baldini, MD [d], Antonio Stecco, MD PhD [e,*],

Materials and Method

Azienda Ospedaliero Universitaria Careggi

- 42 patients (29 female and 13 male). Totally 70 symptomatic hands.
- The criteria for diagnosing CTS were clinical (Phalen and Tinel test positive) and electromyographic (positive EMG showing a decrease in nerve conduction within the last six months)
- **Exclusion:** congenital coagulopathies, use of oral anticoagulant therapy, previous treatments that ended in less than 3 months, only weakness symptoms, concomitant tumors and systemic neurological and rheumatological pathologies
- Randomized into **two groups** (homogeneous for age, sex, and severity):
- **Group 1** (35 hands): fascial manipulation© 3 sessions (1/week)
- **Group 2** (35 hands): laser-therapy 5 daily session

Materials and Method

Azienda Ospedaliero Universitaria Careggi

- Self-assessment **Boston questionnaire (BCTQ) :** severity of the symptoms and functional status
- **Visual Analogue Scale (VAS)** of the mean pain
- **To** (before treatment),
- **T1** (10 days after the last treatment)
- **T2** (3 months after the last treatment)

- The **laser** is an **infrared diode** (M300 level laser)
- Wavelength of 780,800 nm
- Power between 1000 and 3000 mw CW

Results

Azienda Ospedaliero Universitaria Careggi

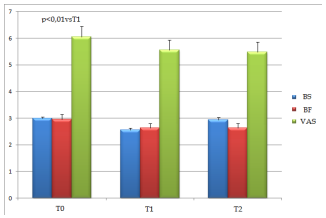

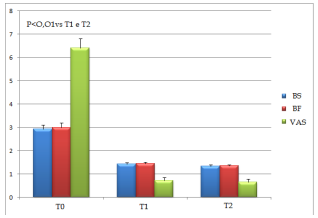

Discussion

Azienda Ospedaliero Universitaria Careggi

Table 1 Mean values± standard deviation for each measurement and *p* value of the comparisons between groups at each single times. (T0: visit pre treatment; T1: visit 10 days after the end of the treatment; T2: visit at 3 months after the end of the treatment; FM: Fascial Mnipulation group; LLLT: Low intensity laser therapy group; BS: Boston symptomatic scale; BF: Boston Functional scale; VAS: visual analogical scale; SD standard deviation).

Time	Scale	Group	Mean	SD	*P* value
TO	BS	MF	3.03	0.77	0.803
		LLLT	3.05	0.35	
	BF	MF	3.1	0.98	0.487
		LLLT	2.9	0.89	
	VAS	MF	6.00	2.6	0.144
		LLLT	5.51	2.24	
T1	BS	MF	1.36	0.27	<0.0001
		LLLT	2.67	0.47	
	BF	MF	1.41	0.3	<0.0001
		LLLT	2.58	0.79	
	VAS	MF	0.8	0.96	<0.0001
		LLLT	5.00	2.07	
T2	BS	MF	1.28	0.28	<0.0001
		LLLT	3.00	0.31	
	BF	MF	1.32	0.32	<0.0001
		LLLT	2.63	0.94	
	VAS	MF	0.71	0.93	<0.0001
		LLLT	5.03	2.02	

Table 2 Mean values± standard deviation of the different between T0-T1 and T0-T2. *P* value of the different between T0-T1 and T0-T2 in each group for each evaluation. (T0: visit pre treatment; T1: visit 10 days after the end of the treatment; T2: visit at 3 months after the end of the treatment; FM: Fascial Manipulation group; LLLT: Low intensity laser therapy group; BS: Boston symptomatic scale; BF: Boston Functional scale; VAS: visual analogical scale; SD standard deviation).

Comparison	Groups	Evaluation	Mean	SD	*p* value
T0-T1	MF	BS	1.67	0.69	<0.0001
		BF	1.69	0.88	<0.0001
		VAS	5.2	2.41	<0.0001
	LLLT	BS	0.38	0.44	<0.0001
		BF	0.32	0.16	<0.0001
		VAS	0.51	0.51	<0.0001
T0-T2	MF	BS	1.75	0.74	<0.0001
		BF	1.78	0.95	<0.0001
		VAS	5.29	2.42	<0.0001
	LLLT	BS	0.06	0.11	0.0054
		BF	0.27	0.59	0.0107
		VAS	0.49	0.98	0.006

This study supports the conclusion that FM is more effective than LLLT in the conservative treatment of patients affected by CTS. The patients (Group A), treated with FM showed improvement of the BCTQ and VAS that was main- tained at the follow up (T2) with a high level of significance ($p < 0.001$)

Conclusion

FM appears to be an appropriate treatment not only for musculoskeletal dysfunction but also for common nerve entrapments as in carpal tunnel syndrome. **The method is effective and non-invasive**. It gives excellent results for the relief of local symptoms and for restoring functionality with benefits that remain at three month follow up.

maybe…

Due to treatment failure of 1%e25% and complications of carpal tunnel releases (Neuhaus et al., 2012) we suggest that a conservative treatment of FM should be prescribed first.

Important Observations

CTS and previous injuries…is there a correlation?

In this clinical study:

- **70%** of the patients had previous **fractures** or **surgery** in the **hand** and/or **wrist (ca, di)**
- **40%** previous **cervical traumas (cl)**
- **50%** previous pathologies in the **shoulder (sc, hu)**

The success of FM in CTS in our study also supports the theory of myofascial continuity between the flexor carpi retinaculum, palmar aponeurosis and antebrachial and brachial fascia (Stecco et al., 2010)

The Myofascial Sequence

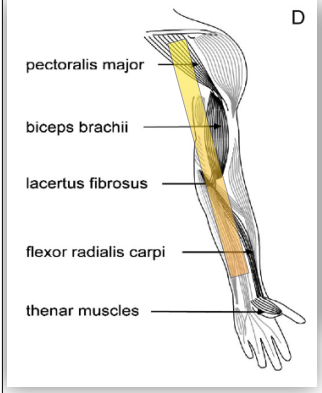

pectoralis major | lacertus fibrosus | flexor radialis carpi

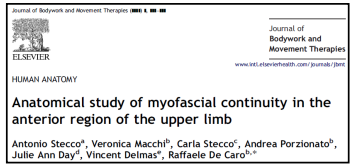

Journal of Bodywork and Movement Therapies

ELSEVIER

HUMAN ANATOMY

Anatomical study of myofascial continuity in the anterior region of the upper limb

Antonio Stecco[a], Veronica Macchi[b], Carla Stecco[c], Andrea Porzionato[b], Julie Ann Day[d], Vincent Delmas[e], Raffaele De Caro[b, *]

Don't Forget…

Thank you for your attention…