ANATOMY OF THE FASCIAL SYSTEM

Antonio Stecco M.D.

Department of Human Anatomy and Physiology, University of Padova, Italy

WHAT IS THE SUPERFICIAL FASCIA?

- The Anatomical Terminology [FCAT] suggested that the term fascia could be used to indicate a sheath, sheet or other dissectible connective tissue aggregations.
- The aim of our studies is to demonstrate the constant presence of a sheet of connective tissue inside the subcutaneous tissue.

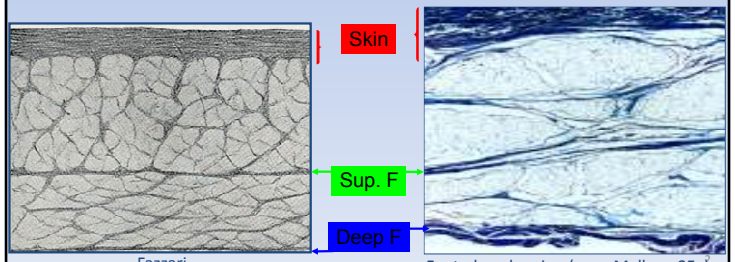

Fazzari

Foot: dorsal region (azan-Mallory, 25x)

THE SUPERFICIAL FASCIA OF THE ABDOMEN

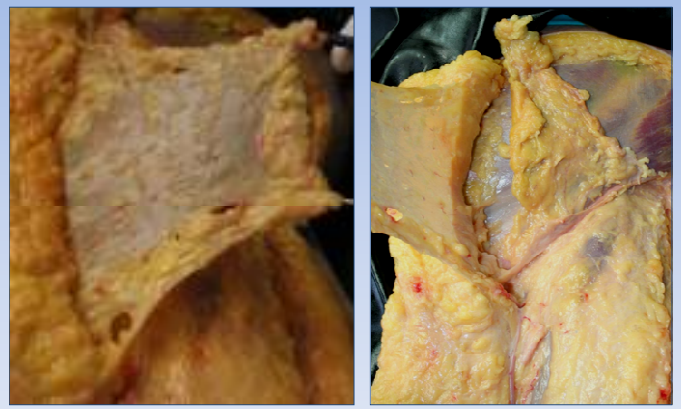

A fibrous sheet, corresponding to the Scarpa's fascia, could be easily isolated inside the subcutaneous adipose tissue.

Computer axial tomography scan

L2

The superficial fascia of the back

In the dorsum, the superficial fascia appears as a thick fibrous lamina extending in a homogenous manner from the neck to the gluteal region, easily separable from the deep fascia. It adheres to the deeper layers along the spinous processes and along the inferior margin of the scapula.

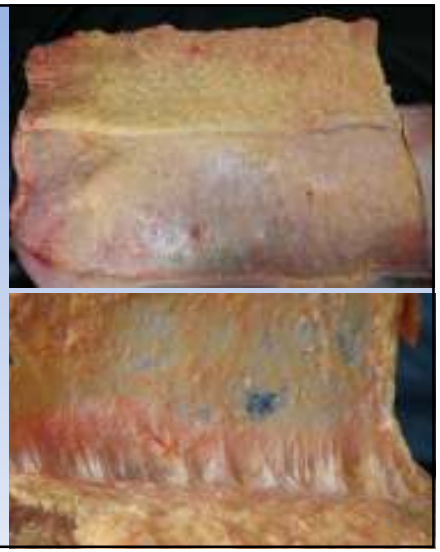

Superficial fascia

At **MRI** in T1 weight imaging the superficial fascia is easy to see both in coronal and in sagital planes.

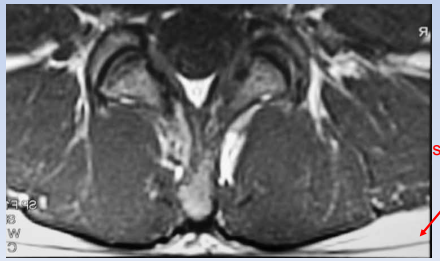

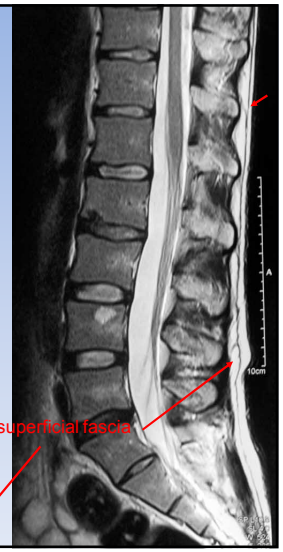

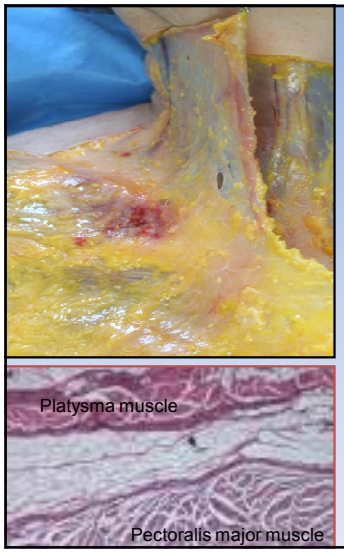

The SUPERFICIAL FASCIA IN THE THORACIC REGION

(Stecco et al, JBMT, 2009)

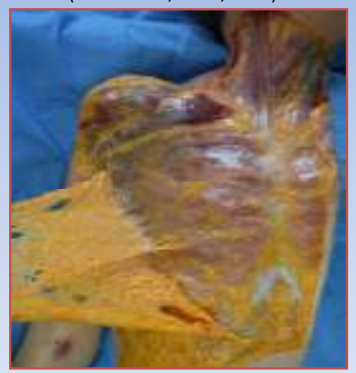

The SF envelops the platysma muscle and it is easily separable from the deep fascia, except at the level of the 6° rib.

The superficial fascia of the LIMBS

The SF of the thigh

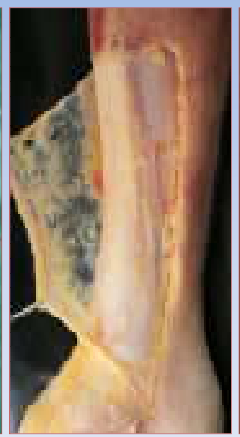

The SF of the leg

The SF of the arm

The SUPERFICIAL FASCIA of the extremities

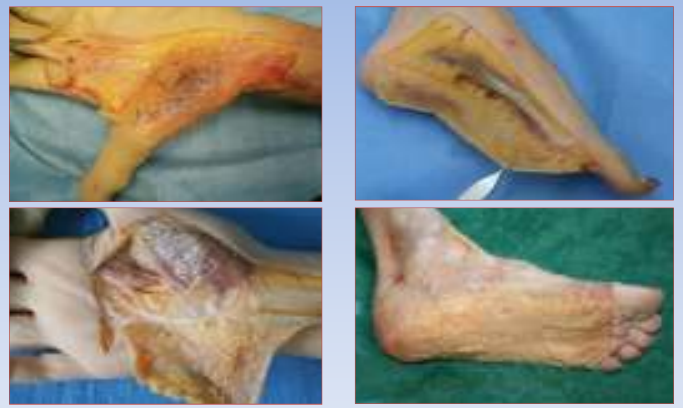

The superficial fascia adheres to the deep fascia and it is also connected with the skin by thick vertical septa.

9

WHAT IS THE SUPERFICIAL FASCIA?

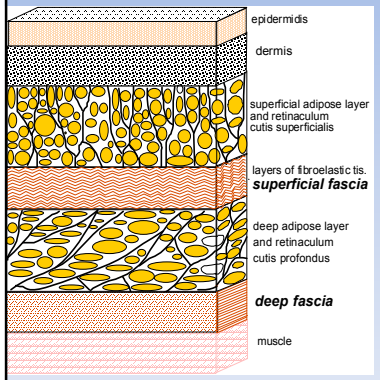

- The superficial fascia could be recognized in almost all the human body, even if with regional specialization.
- Vertical/oblique septa connect the superficial fascia to the skin (retinaculum cutis superficialis or skin ligaments) and the deep fascia (retinaculum cutis profundus) forming a 3-D network between the fat lobules.

REGIONAL SPECIALIZATIONS IN THE FACE

- In the face, we can recognize three different patterns.
- Changes in the quantitative and qualitative characteristics of the retinacula cutis and superficial fascia of the face, may contribute to ptosis of facial soft tissues during aging.



Stecco et al (2009) Histotopographic study of the fibroadipose connective cheek system. CTO

The appearance of the SMAS in CT

(Stecco et al, Italian J of Anatomy, 2008)

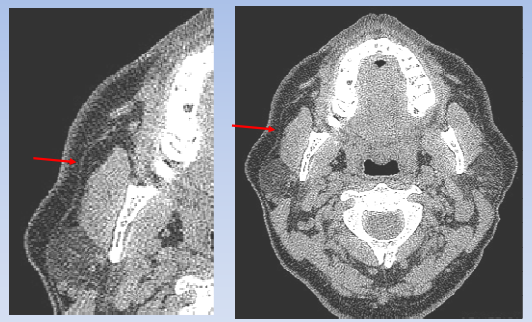

In axial CT images, the SMAS appears as a relatively hyperdense tortuous line between the hypodense superficial adipose tissue (SAT) and the hypodense deep adipose tissue (DAT).

Histological features of the SUPERFICIAL FASCIA

Superficial fascia of the thigh (azan-Mallory, 25x)

Superficial fascia of the leg (immunohistochemical stain anti-S100 antibody, 100x)

Superficial fascia in the temporal region (van Gieson stain, 100x)

SUPERFICIAL FASCIA AND MUSCLES

- In humans, muscular fibers can be found inside the superficial fascia, particularly in the neck (platysma muscle), in the face (SMAS), in the anal region (external anal sphincter), in the scrotum (dartos).
- The superficial fascia is homologous to the cutaneous muscle layer (panniculus carnosus) found in other mammals.

Resistance to traction in different directions

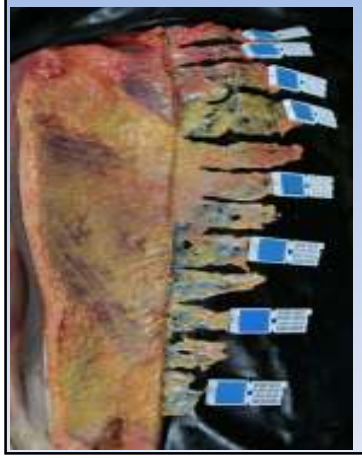

Mean value of resistance to traction:
SF of the dorsum: 8.5 Kg
SF of the abdomen: 2.8 Kg
SF of the leg: 1.7 Kg

Mean value of resistance to traction:
SF of the dorsum: 6 Kg
SF of the abdomen: 5.5 Kg
SF of the leg: 1.4 Kg

Resistance to traction in different directions

In the dorsum, the superficial fascia shows a great variation in its behaviour, going from a maximum of 10 Kg to a minimum of 0.5 Kg.

THE SUPERFICIAL FASCIA AND VESSELS

Plastinated section, saphenous v.

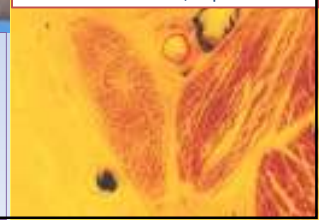

In some regions the superficial fascia splits, forming special compartments around major subcutaneous veins and lymphatic vessels. In this way it protects the vessels during movements and maintains the vessels open.

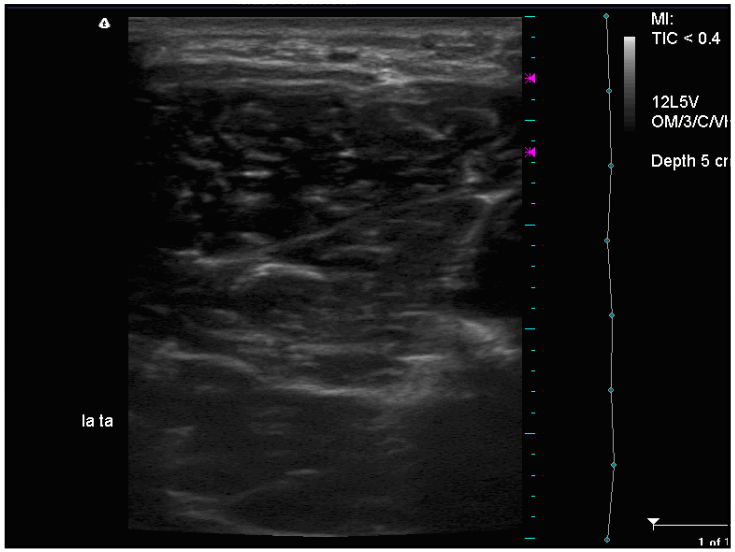

The superficial fascia and the vessels

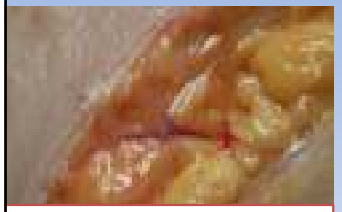

Perforantes vessel crossing the SF

Vascular plexus inside the fascia

Inside the superficial fascia we can recognize the superficial vascular plexus and numerous lymphatic ducts.
Also the perforantes vessels have to cross the superficial fascia to reach the skin.

The lymphatic ducts are inside the SF

SUPERFICIAL Fascia AND NERVES

Superficial peroneal nerve

The terminal fibers of the nerves inside the superficial fascia: could be this a possible site of compression?

20

The POSSIBLE ROLES OF THE superficial fascia

The features of the SF and its relationships with the surrounding tissues determine:

- **The mobility of skin with respect to the deep planes** (age ptosis and wrinkles, plastic surgery)
- **Protection of the superficial vessels and nerves** (varicose veins, tired feeling and weakness in the legs…)
- **Lymphatic drainage** (lymphoedema, fascitis, cellulitis…)
- **The separation between esteroception** (skin) **and proprioception** (deep fascia)

Normal morphology of Hypodermis

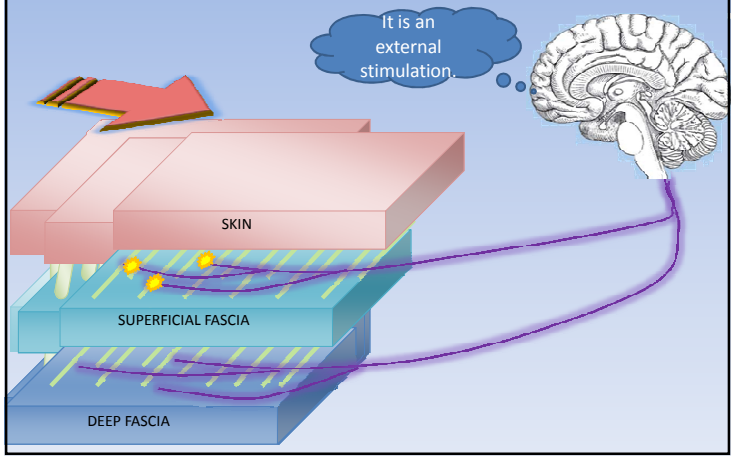

Pathological morphology of Hypodermis

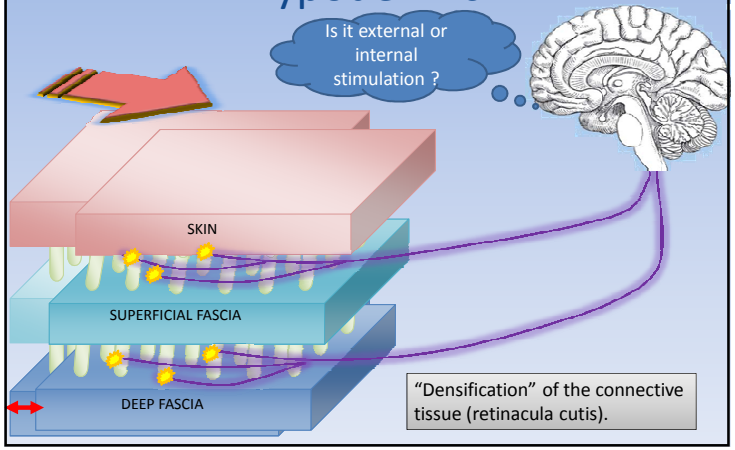

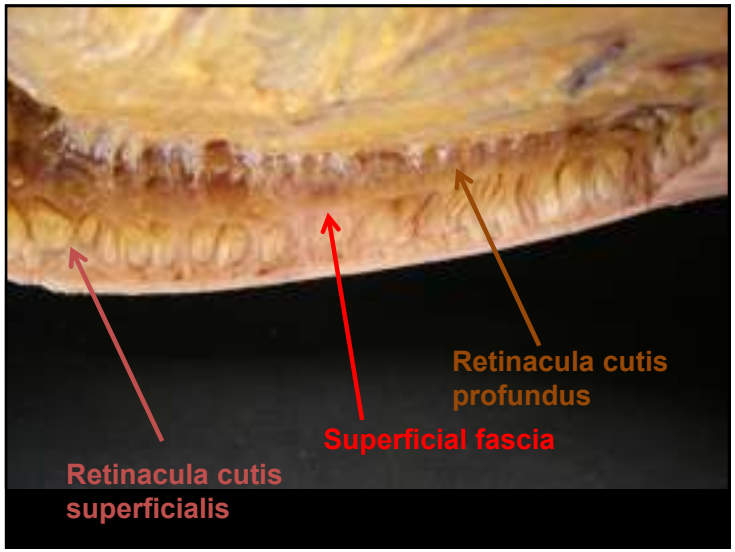

The retinacula cutis

- The retinacula cutis provide an anchorage of skin to underlying tissues and of the superficial fascia to the deep fascia.
- In this way a flexible and yet resistant mechanism of transmission of the mechanical loads from multi-directional forces could be recognized.
- Regional specializations determine the variations in mobility of the skin with respect to underlying tissues.

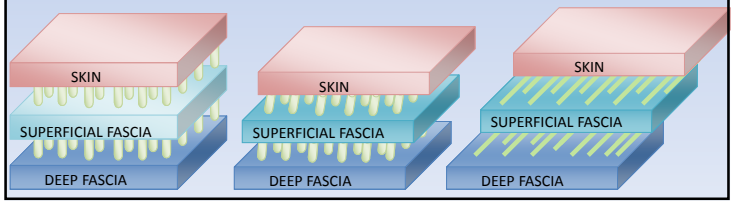

Superficial fascia is more adherent to the skin

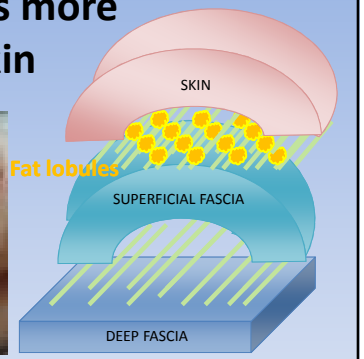

The septa of the retinaculum cutis superficialis are usually many and vertically oriented, while the septa of the retinaculum cutis profondum are less, thinner and with an oblique direction. In this way the superficial fascia is generally more adherent to the skin than to the deep fascia.

GROSS ANATOMY: the fasciae of the thigh

Subcutaneous adipose tissue after having removed the skin

Isolation of the superficial fascia

Deep fascia of the thigh and epimysium of the quadriceps

GROSS ANATOMY: the fasciae of the leg

Superficial fascia

Deep fascia

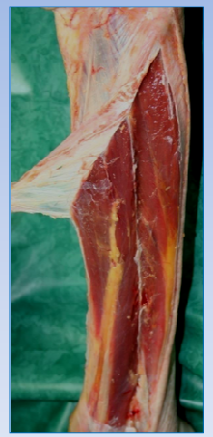

Deep and epimysial fasciae

GROSS ANATOMY: fasciae of the upper limb

Subcutaneous tissue of the forearm

Deep fascia of the posterior region of the forearm

Deep and epimysial fascia of the biceps brachii muscle

MORPHOMETRIC ANALYSIS: the deep fasciae of the limbs

- The deep fascia is easily separable from the epimisyum of the underlying muscles
- It shows aponeurotic features and it is very resistant to traction.
- It presents different thicknesses according to the evaluated zones.

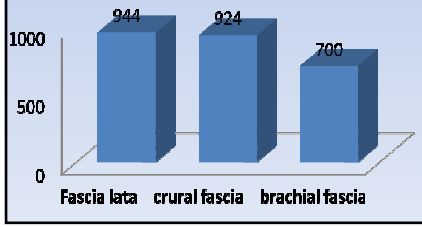

HISTOLOGICAL STUDY: the deep fasciae of the limbs

Multiple layers of undulated collagen fibre bundles form the deep fascia.
In each layer the bundles are parallel to each other.

A thin layer of loose connective tissue separates the different layers. Adjacent layers of collagen fibers show different orientations.

HISTOLOGICAL STUDY: the deep fasciae of the limbs

In the muscular fascia of the upper limb, few elastin fibers are also present. They form an irregular mesh.

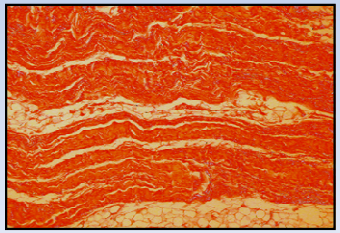

In the deep fascia of the inferior limb, we found very few elastin fibers.

3D RECONSTRUCTION of the collagen fibers



The collagen fibers are disposed parallel to each other to form 2/3 layers (277.6 µm). In adjacent layers, the bundles show different orientations, creating an angle of 78°. The collagen volume fraction is about 18%.

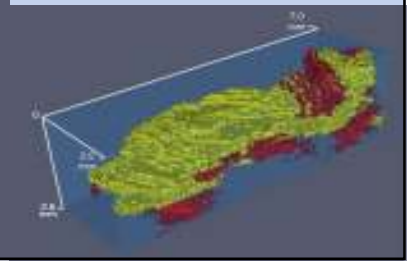

3D RECONSTRUCTION of the elastic fibers





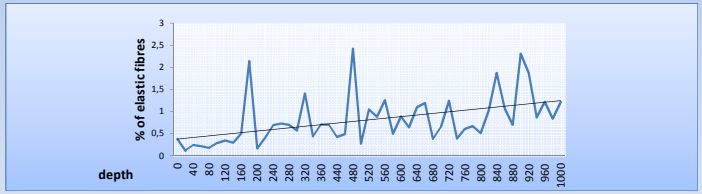

Only a few, short elastic fibres are present, forming an irregular mesh. Their volume is less than 1%.
Their concentration increases descending to the deeper layers.

THE DEEP FASCIAE: from an irregular fibrous tissue to a multilayer organization (Stecco et al, 2008)

Serial sections of fascia



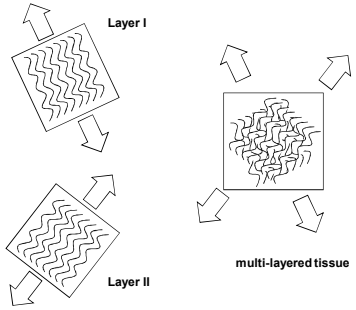

Thanks to the different orientations of the collagen fibers in the layers, the fascia has strong resistance to traction even when it is exercised in different directions.

The multilayer structure of the deep fasciae of the limbs

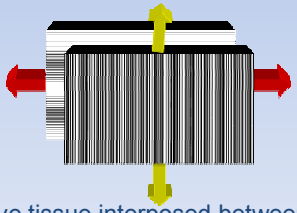

The presence of loose connective tissue interposed between adjacent layers permits local sliding, and so from a mechanical point of view the single layers could be considered independently.

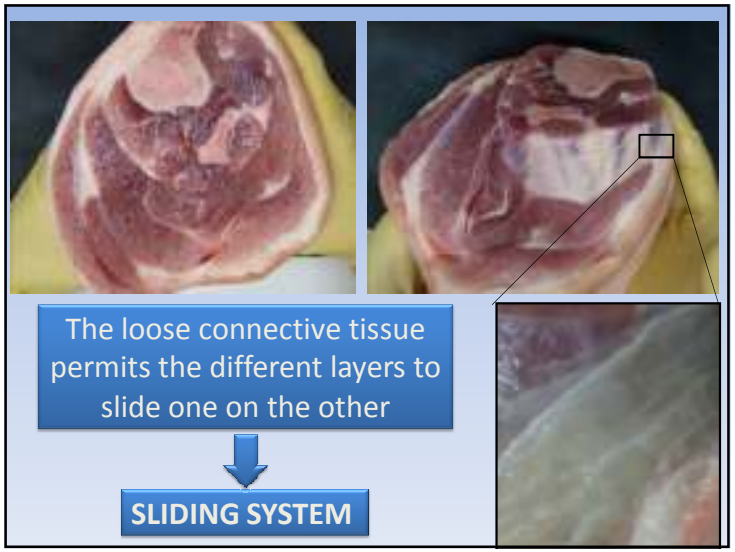

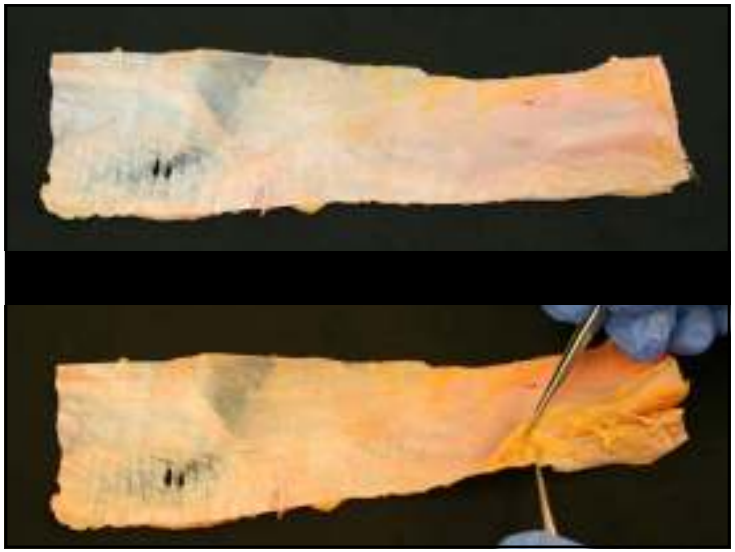

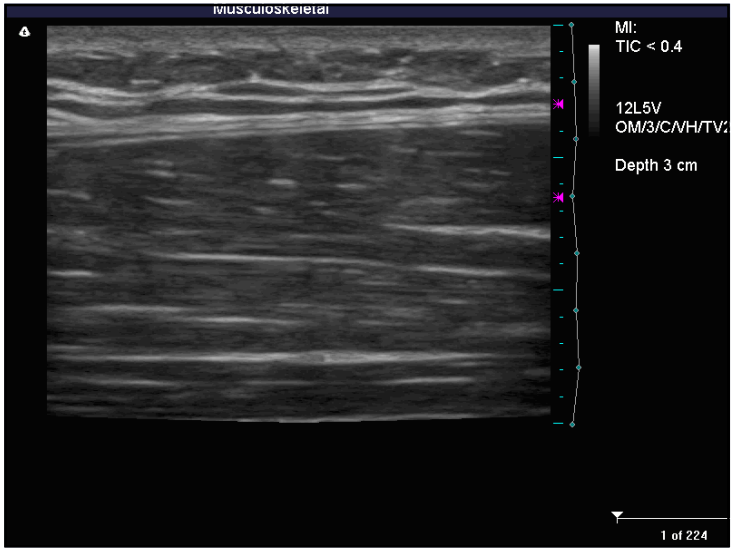

Presence of HA in the connective tissue

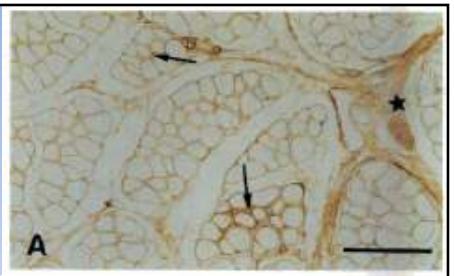

A) Vastus lateralis muscle. Hyaluronan is present in the endomysium surrounding the individual muscle fibers (arrows). The staining is pronounced in the perivascular and perineural connective tissue (asterisk).

"Hyaluronan is ubiquitously distributed in the extracellular space of higher animals; the highest concentrations are found in soft connective tissues"

TC Laurent and JR Fraser; Hyaluronan; The FASEB Journal, 1992 Vol 6, 2397-404,

Presence of HA in the connective tissue

"HA is present in most connective tissues and abundant in loose connective tissue."

Piehl-Aulin K et al; Hyaluronan in human skeletal muscle of lower extremity: concentration, distribution, and effect of exercise; J Appl Physiol. 1991 Dec;71(6):2493-8.

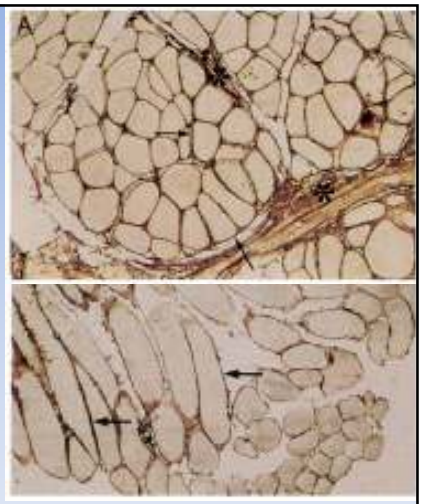

Quadriceps femoris muscle

Presence of HA under deep fascia

"Hyaluronic acid is localized to the deep or muscular surface (arrow) of the deep fascia"

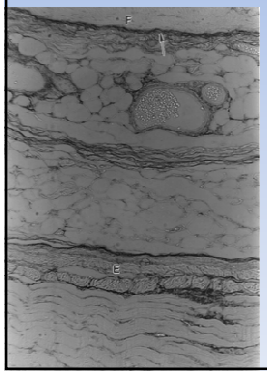

McCombe D et al; The histochemical structure of the deep fascia and its structural response to surgery; J Hand Surg Br. 2001 Apr;26(2):89-97.

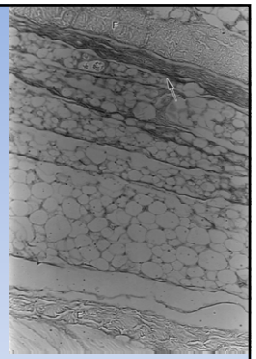

"The deep fascia is a simple structure of connective tissue, which produces a gliding interface in conjunction with the epimysial capsule of the muscle and the intervening areolar tissue plane."

Deep fascia produces HA

"Three distinct layers are identified in the retinaculums of both the ankle and wrist: the inner gliding layer, with hyaluronic acid-secreting cells."

Klein DM et al; Histology of the extensor retinaculum of the wrist and the ankle; J Hand Surg Am. 1999 Jul;24(4):799-802.

"The inner gliding surface, characterized by modified fibroblasts secreting hyaluronic acid"

Ellis FD et al;The second annular pulley: a histologic examination.;J Hand Surg Am. 1995 Jul;20(4):632-5.

"The inner layer contained a hyaluronic acid-like substance .The majority of the inner layer cells had the appearance of modified (In fresh unembalmed elderly cadavers)"

Katzman BM et al; Comparative histology of the annular and cruciform pulleys; J Hand Surg Br. 1999 Jun;24(3):272-4.

MRI of the ankle retinacula

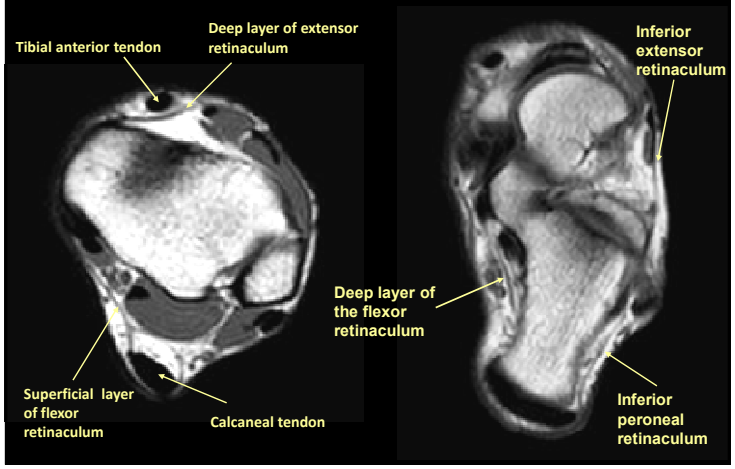

“The retinacula are thickenings of the deep fascia”

Original Paper

The Ankle Retinacula: Morphological Evidence of the Proprioceptive Role of the Fascial System

“They are formed of 2–3 layers of parallel collagen fibre bundles, densely packaged with a little loose connective tissue, without elastic fibres but many nervous fibres and corpuscles”.

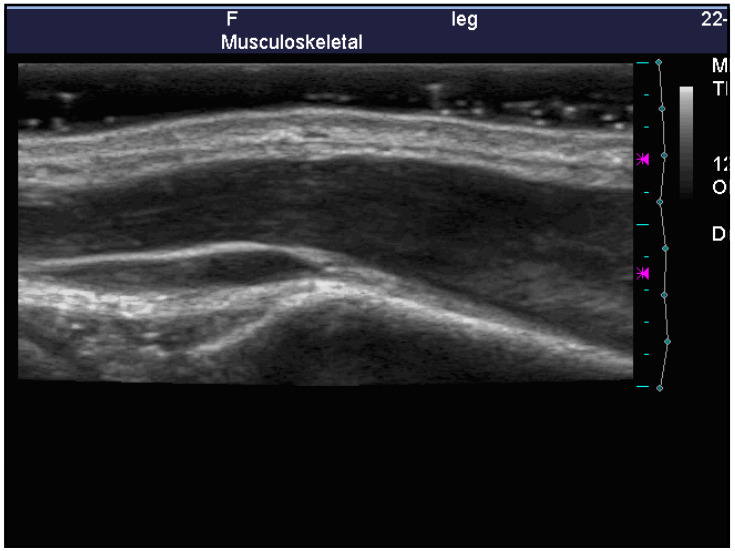

FROM PHYSIOLOGY TO PATHOLOGY

The capacity of the different collagen layers to glide one on the other could be altered in cases of overuse syndrome, trauma or surgery.

Male, 65 ys, diabetic, amputation after 10 months of immobility following trauma

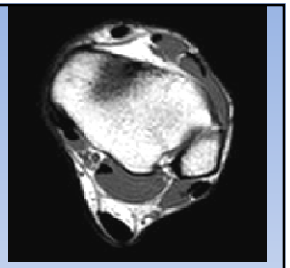

Normal

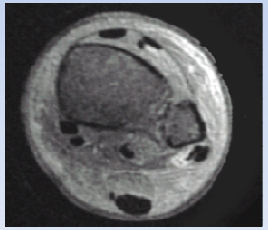

Pathological

FROM PHYSIOLOGY TO PATHOLOGY

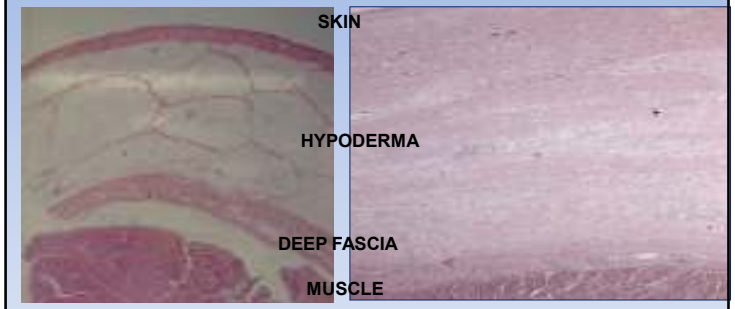

Control

Male, 65 ys, diabetic, amputation after 10 months of immobility following trauma

Anatomy of the retinacula

- A retinaculum, as the name suggests (from Latin *rete* = net) is a network or grid of collagen fibres arranged according to multiple lines of traction, with functions that are distinctly different from those of a ligament.
- The retinacula are in continuity with the fascia. The retinacula form rings around the articulations of the body and, via endofascial collagen fibres arranged in a spiral, they connect proximal articulations with distal articulations

Posterior region of the elbow

Anatomy of the retinacula

- Superior extensor retinaculum, the ligament that binds down the extensor tendons proximal to the ankle joint;
- it is continuous with the deep fascia of the leg. Syn. Ligamentum transversum cruris, superior ret. of extensor muscles, transverse crural ligament, transverse ligament of leg.

This complexity of fibres would not be necessary if the only role of the retinacula were to bind the tendons close to the bones

- The superior retinaculum of the extensor muscles of the foot is situated in the inferior third of the leg where the tendons do not bend like they do under the inferior retinaculum.
- If the only role of the inferior retinaculum of the foot were that of restraint then all of its fibres would be inserted onto bone. Instead many fibres are continuous with the posterior fascia.

MRI of the ankle retinacula

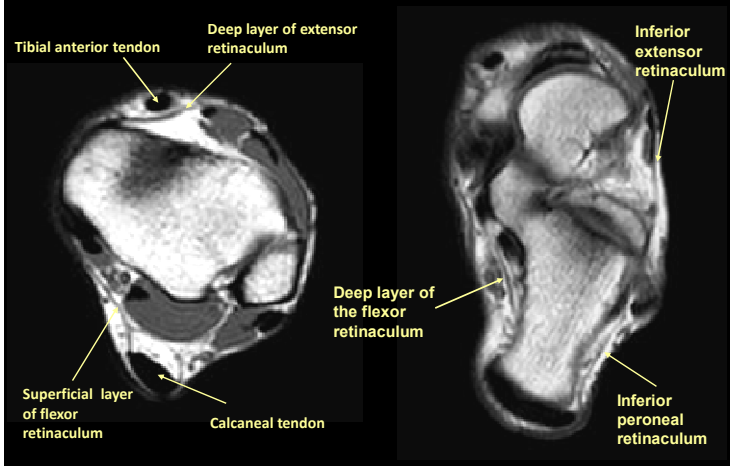

The Ankle Retinacula: Morphological Evidence of the Proprioceptive Role of the Fascial System Carla Stecco et al , Cell Tissues Organs, 2010.

Dissection, histological and immunohistochemical analysis of **27 legs**. MRI on 7 healthy volunteers,17 patients with outcomes of ankle sprain, and 3 amputated legs.

Conclusion: Retinacula are not static structures for joint stabilisation, like ligaments, but a specialization of fascia for local spatial proprioception of foot and ankle movements. …**integrative role of the fascial system in peripheral control of articular motility.**

54

A striking pattern of orientation of fibers in the deep fascia of the ankle was observed under polarized light.

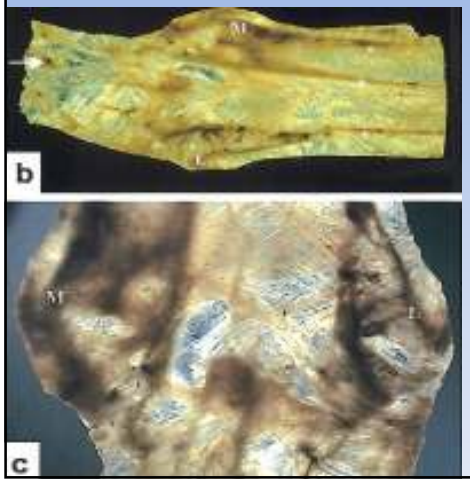

Deep Fascia on the Dorsum of the Ankle and Foot: Extensor Retinacula Revisited ABU-HIJLEH & HARRIS, Clinical Anatomy 2007

55

The fascial planes of the wrist

- Antebrachial flexor retinaculum, thickening of distal antebrachial fascia just proximal to radiocarpal joint. Continuous with extensor retinaculum at margins of forearm. This structure **is distinct** from the transverse carpal ligament, commonly called “the flexor retinaculum” which forms the roof of the carpal tunnel
- Syn. Flexor retinaculum of forearm, palmar carpal ligament. (Stedman’s, 1995)

The fascial planes of the wrist

The MRI images permit to appreciate the relationships between the flexor retinaculum of carpi and the transverse carpal ligament.

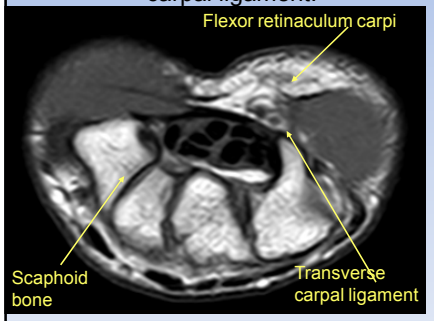

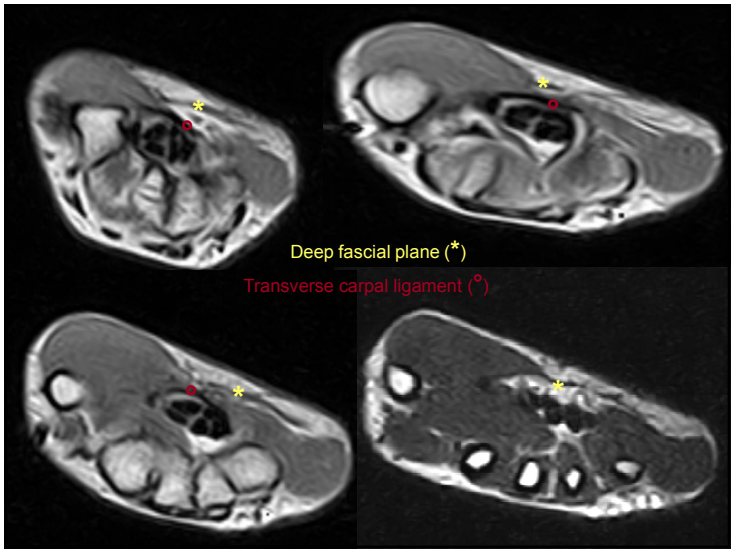

This complexity of fibres would not be necessary if the only role of the retinacula were to bind the tendons close to the bones

- Around the **knee** the patellar retinaculum and the popliteal retinaculum do not maintain any tendons close to the bone.
- At the wrist the transverse carpal ligament restrains the flexor tendons whilst the flexor retinaculum is effectively independent.

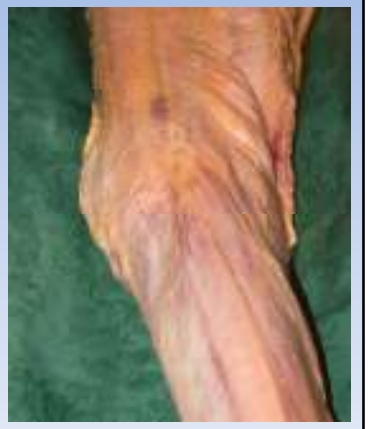

The anterior knee pain

Male, 65 ys, pain in the anterior region of the right knee
MRI: hyper-intense signal of the medial retinaculum(*)

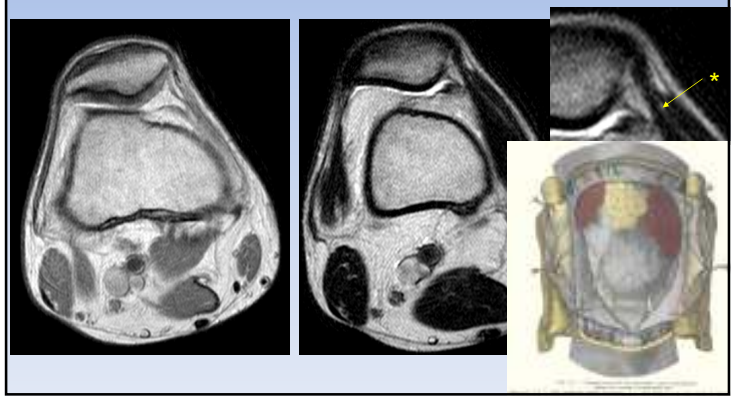

Patellar tendon tension measured in 10 cadaver knees, varying degrees of flexion. **Patellar tendon tension increased after removal of peripatellar retinaculum** (at 0° and 60°) - indicates load-sharing function of retinaculum as part of extensor mechanism.
Powers CM et al. 2006 J Bone Joint Surg Am

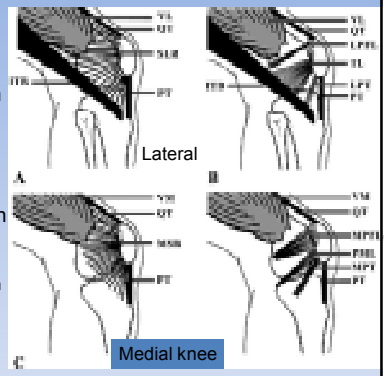

Extensor Retinaculum Impingement in the Athlete: A New Diagnosis.
Vanheest AE, (Orthopaedic Surgeon, Minnesota) 2007 Am J Sports Med.
Extensor retinaculum impingement, a new diagnosis for wrist pain, in athletes performing repetitive wrist hyperextension

61

All of these fibres **must be able to glide independently** from one another within the ground substance.

This independence has become so reinforced in the transversal fibres that in some parts they have formed retinacula.

A retinaculum is formed by a network of fibres that cross over each other and at the same time slide independently from one another.

The collagen fibres of the retinacula do not stop at joints but continue, in a helicoidal pattern, along the various fasciae

Physiology

- The CF is located over the muscular fibres of the mf unit of fusion and between the tendons of the two segmentary mf units.
- Just like the director of an orchestra it directs the *crescendo* of one mf unit and the *diminuendo* of the other.
- This coordination is effectuated by tendons tensioning the retinacula together with the consequential activation of the Golgi tendon organs.